

Agytumrok differenciáldiagnosztikája

VÁRALLYAY PÉTER
OMIII

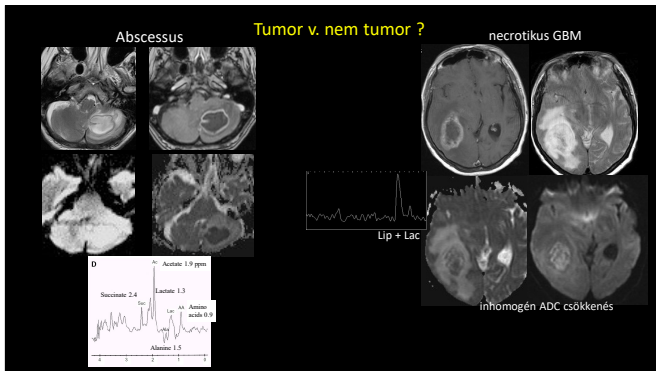
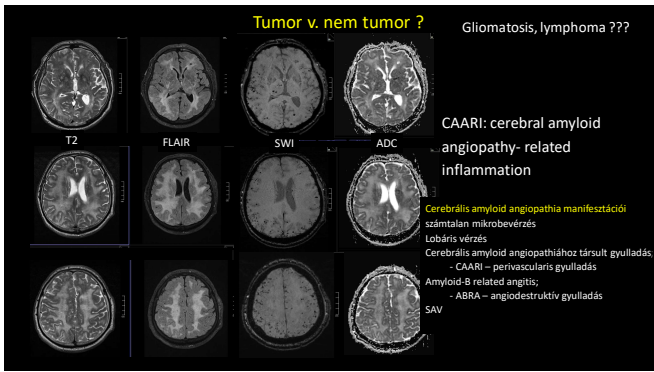
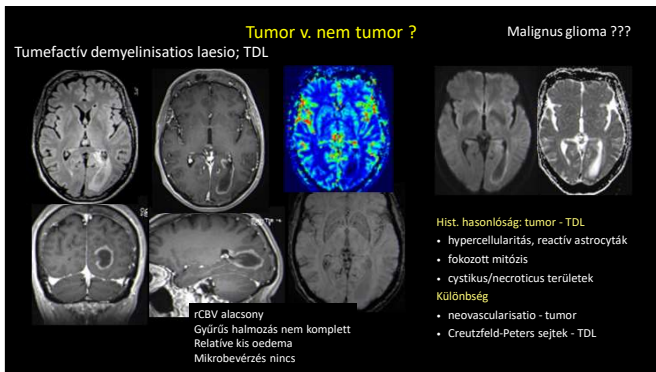
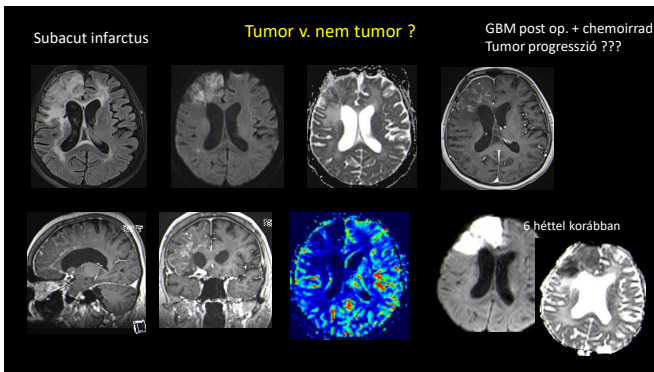
Agytumrok differenciáldiagnosztikája

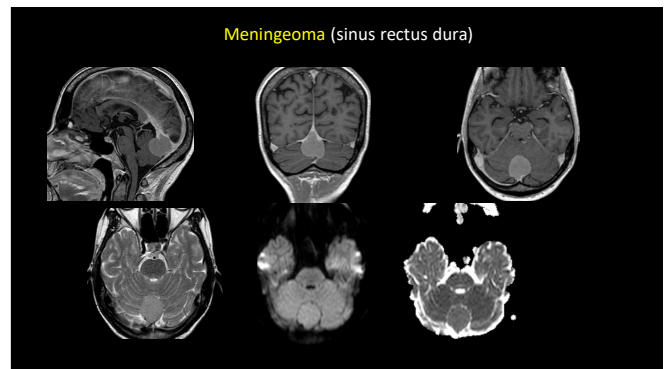
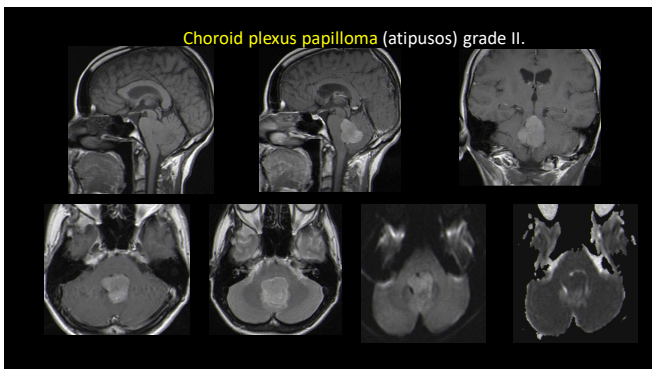
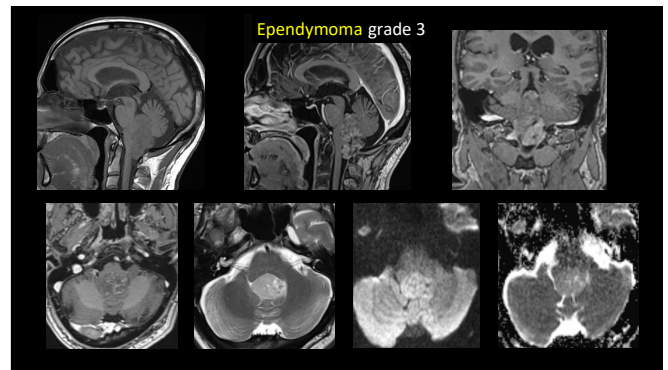
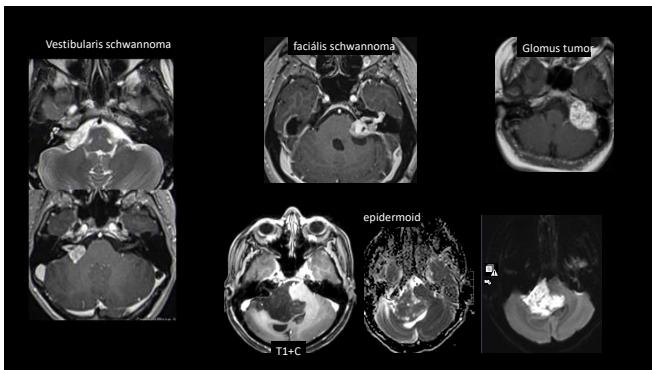
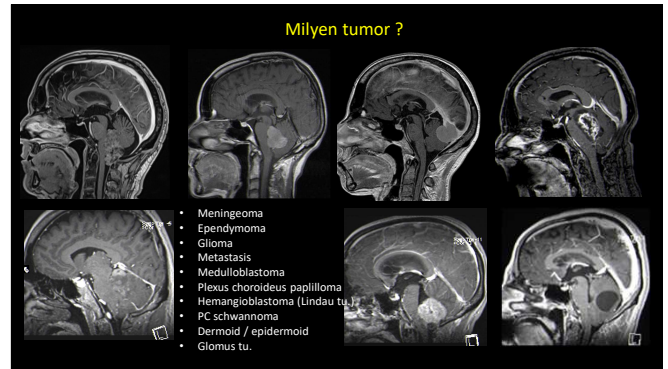
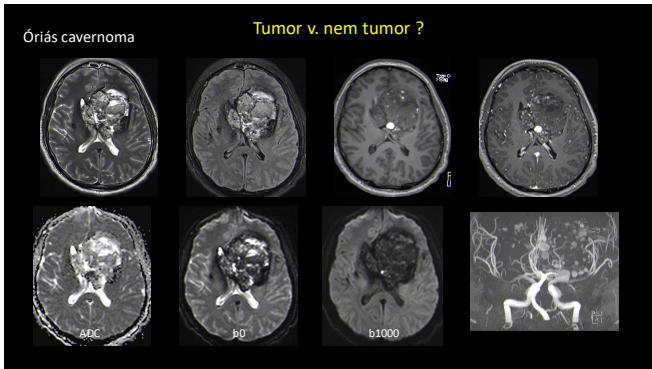
Preterápiásan:

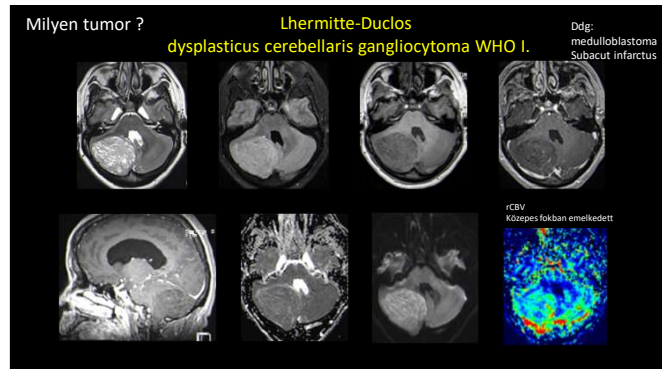
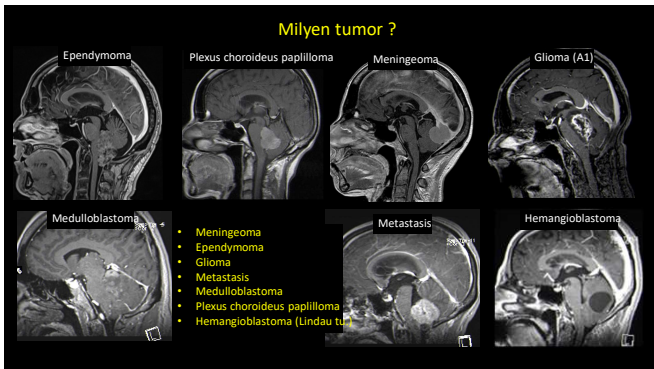
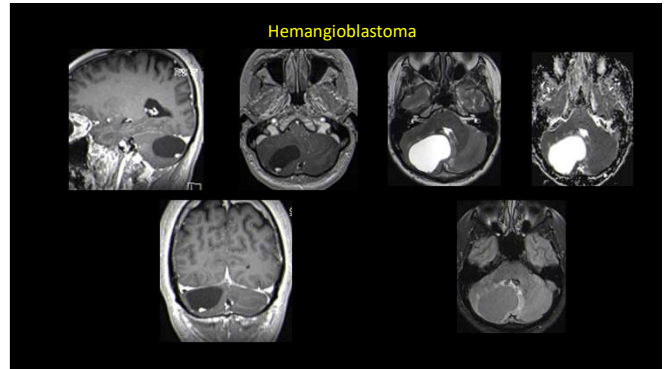
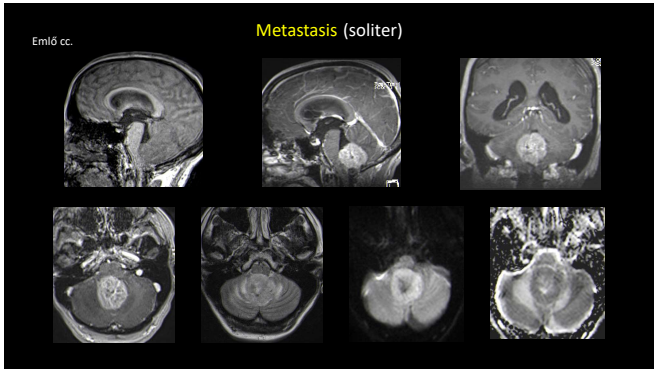
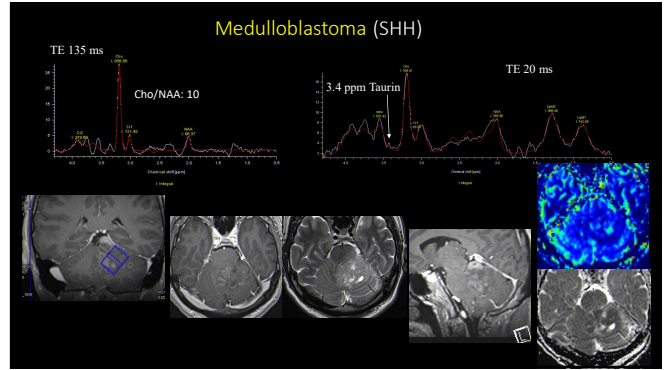
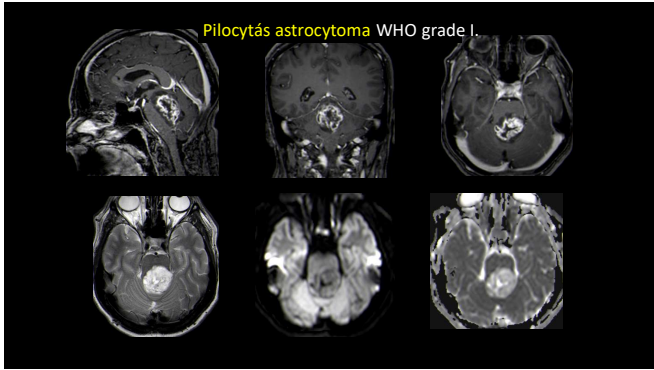
- tumor v. nem tumor
- milyen tumor
- malignitási fokozat (grading)
- kiterjedés (oedéma, gliosis v. infiltráló tumor)
- elokvens területek, pályák

Postterápiásan:

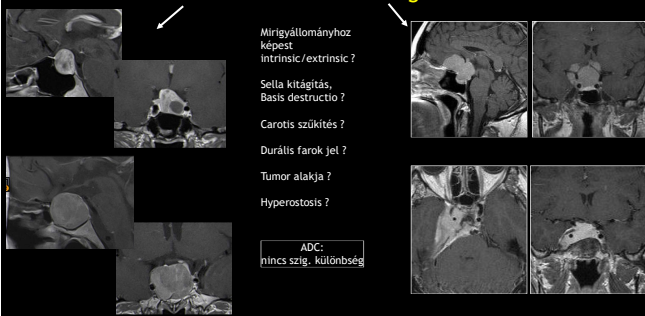
- residuum, recidiva
- postterápiás eltérések
- sugárnekrozis
- pseudoprogressio
- pseudoregressio







Milyen tumor? **Macroadenoma v. meningeoma**



Mirigyállományhoz képest intrinsíc/extrinsíc?

Sella kitégítés, Basis destructio?

Carotis szűkítés?

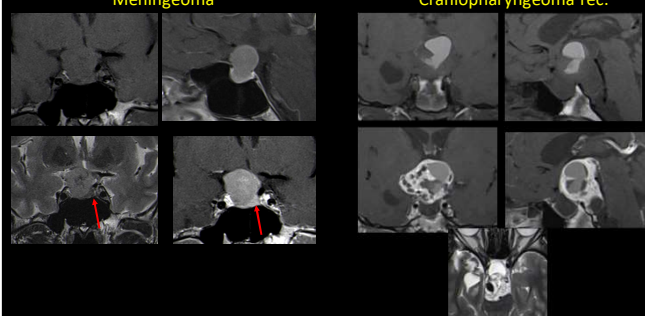
Durális farok jel?

Tumor alakja?

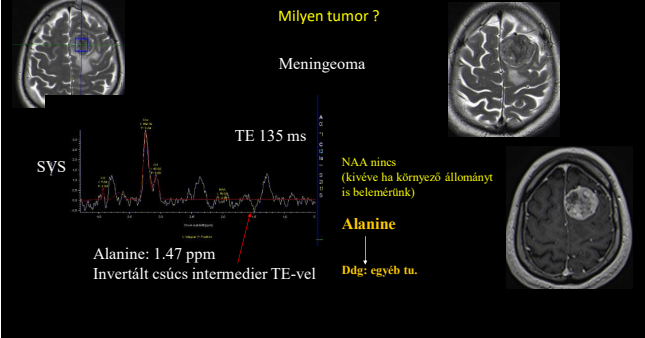
Hyperostosis?

ADC: nincs szig. különbség

Milyen tumor? **Meningeoma** vs **Craniopharyngeoma rec.**



Milyen tumor? **Meningeoma**



TE 135 ms

SYS

Alanine: 1.47 ppm

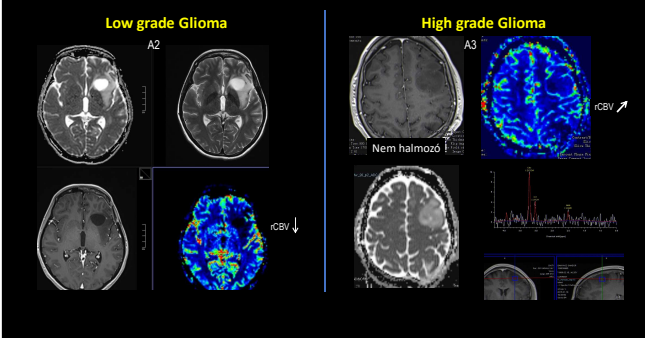
Invertált csúcs intermedier TE-vel

NAA nincs (kivéve ha környező állományt is belemértünk)

Alanine

Ddg: egyéb tu.

Low grade Glioma vs **High grade Glioma**



A2

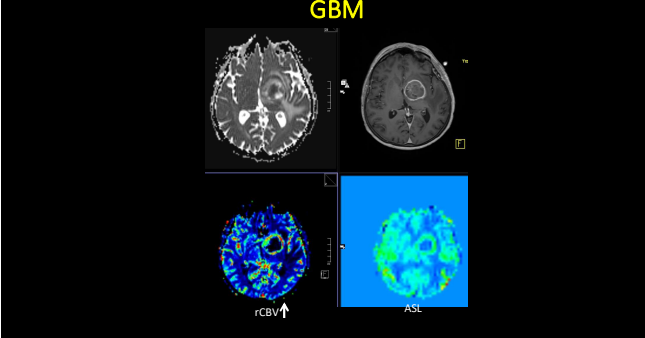
A3

Nem halmozó

rCBV ↑

rCBV ↓

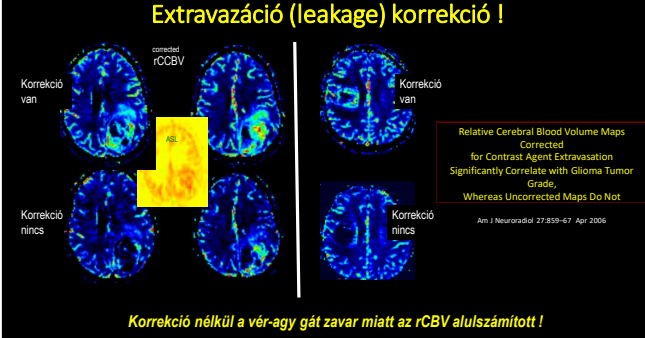
GBM



rCBV ↑

ASL

Extravazáció (leakage) korrekció!



Korrekció van

Korrekció nincs

Relative Cerebral Blood Volume Maps Corrected for Contrast Agent Extravasation Significantly Correlate with Glioma Tumor Grade, Whereas Uncorrected Maps Do Not

Am J Neuroradiol 27:859-67 Apr 2008

Korrekció nélkül a vér-agy gát zavar miatt az rCBV alulszámított!

